



ROSENBERG  
SCHOOL of  
OPTOMETRY

2020

# Alternative Therapies for Treatment of Keratoconjunctivitis Sicca Associated with Sjogren's Syndrome

Brittney M. Brady OD, FAAO  
*Illinois College of Optometry, bbrady@ico.edu*

Michelle K. Man OD, FAAO  
*Illinois College of Optometry, michman@ico.edu*

Follow this and additional works at: [https://athenaeum.uiw.edu/optometric\\_clinical\\_practice](https://athenaeum.uiw.edu/optometric_clinical_practice)



Part of the [Optometry Commons](#), and the [Other Medicine and Health Sciences Commons](#)

The Athenaeum provides a publication platform for fully open access journals, which means that all articles are available on the Internet to all users immediately upon publication. However, the opinions and sentiments expressed by the authors of articles published in our journal does not necessarily indicate the endorsement or reflect the views of the University of the Incarnate Word and its employees. The authors are solely responsible for the content of their work. Please address questions to [athenaeum@uiwtx.edu](mailto:athenaeum@uiwtx.edu).

### Recommended Citation

Brady BM, Man MK. Alternative Therapies for Treatment of Keratoconjunctivitis Sicca Associated with Sjogren's Syndrome. *Optometric Clinical Practice*. 2020; 2(2):12. doi: 10.37685/uiwlibraries.2575-7717.2.2.1003. <https://doi.org/10.37685/uiwlibraries.2575-7717.2.2.1003>

This Case Report is brought to you for free and open access by The Athenaeum. It has been accepted for inclusion in *Optometric Clinical Practice* by an authorized editor of The Athenaeum. For more information, please contact [athenaeum@uiwtx.edu](mailto:athenaeum@uiwtx.edu).

---

# Alternative Therapies for Treatment of Keratoconjunctivitis Sicca Associated with Sjogren's Syndrome

## Abstract

**Background:** Sjogren's syndrome is a chronic, systemic autoimmune disorder, which often results in significant ocular surface disease. Dry eye associated with Sjogren's syndrome is a multifactorial disease which leads to decreased function of the lacrimal glands and altered tear composition. There currently are numerous anti-inflammatory methods used for treatment of this disease.

**Case Report:** This case report will focus on the use of amniotic membrane placement and autologous serum tears to facilitate a successful scleral contact lens fit allowing for reduced ocular inflammation and discomfort associated with Keratoconjunctivitis sicca due to Sjogren's syndrome.

**Conclusion:** Clinical management of keratoconjunctivitis sicca due to Sjogren's syndrome can be challenging. Diagnosis often requires numerous in office testing including Schirmer I/II, TBUT, sodium fluorescein stain, and osmolarity. Such testing can be repeated over time to monitor for improvement with addition of each new therapy. Various treatment modalities such as topical lubricants, cyclosporine, autologous serum tears, or amniotic membranes have been proven to provide short-term benefits and excellent maintenance of symptoms. Utilizing such treatments to promote an ideal scleral contact lens fit provides lasting benefits of corneal clarity and stable vision.

## Keywords

Keratoconjunctivitis sicca, Sjogren's syndrome, sicca syndrome, SS, superficial punctate keratitis, amniotic membrane, autologous serum tears, scleral contact lenses, ocular surface disease

## Creative Commons License



This work is licensed under a [Creative Commons Attribution-Noncommercial 4.0 License](https://creativecommons.org/licenses/by-nc/4.0/)

## INTRODUCTION

Keratoconjunctivitis sicca (KCS) is an ocular surface disease, first described by Henrik Sjogren, and is characterized by inflammation resulting in corneal and conjunctival staining.<sup>1,2</sup> The term KCS is used synonymously with dry eye syndrome (DES).<sup>2</sup> In the past, two distinct etiologies of DES were described as aqueous-deficient and evaporative.<sup>2</sup> Aqueous-deficient DES was further distinguished as Sjogren's Syndrome (SS) dry eye or non-SS dry eye.<sup>2</sup> The new classification scheme of DES acknowledges that aqueous-deficient and evaporative DES are not mutually exclusive, but that there is overlap due to the cyclical nature of inflammation, tear film instability and hyperosmolarity in DES.<sup>3</sup> In particular, SS dry eye, which had traditionally been categorized as strictly aqueous-deficient DES, may have an evaporative component due to associated meibomian gland dysfunction (MGD).<sup>3-5</sup>

Therefore, clinical management of KCS caused by SS, a chronic inflammatory autoimmune disease, can be challenging. Roughly 40% of SS occurs in isolation and is considered primary SS, while approximately 60% occurs concurrently with another rheumatic disease and is considered secondary SS.<sup>6</sup> Altered tear composition due to lacrimal gland infiltration in SS leads to ocular surface inflammation and epithelial disruption with resultant discomfort and blurred vision.<sup>6,7</sup> The clinical presentation of KCS secondary to SS is quite variable but managing inflammation while re-establishing the natural tear balance on the ocular surface is essential for the successful treatment of this condition.

## CASE REPORT

A 78-year-old Caucasian female presented for examination with complaints of a "stabbing pain" in the temporal corner OS with associated redness and crusting for five days. She was previously diagnosed with KCS OU due to secondary SS by another clinician. This diagnosis was made due to low Schirmer I test and a systemic history of SS and scleroderma. The patient was currently adherent with the following regimen to treat her condition: cyclosporine 0.05% ophthalmic solution BID OU, preservative-free artificial tears eight times per day OU, and 0.02% hypochlorous acid lid spray QD OU. Additionally, she noted previously unsuccessful use of punctual plugs OU (unknown timeline), as well as amniotic membrane placement OS 2 months ago, which provided initial improvement in corneal clarity but no long-term benefits. In addition to KCS OU, her ocular history was significant for bilateral pseudophakia, mild normal tension glaucoma OU (monitored without treatment), operculated retinal hole OD, and MGD OU. She reported a surgical history of LASIK OU 19 years prior (monovision: OD corrected

for near and OS corrected for distance), cataract surgery OU 7 years ago with toric IOL OD and monofocal IOL OS (monovision: OD corrected for near and OS corrected for distance), LipiFlow® (Johnson & Johnson Vision Science; New Brunswick, New Jersey) thermal pulsation treatment OU 1 year ago, and an appendectomy 57 years ago. The patient's medical history was positive for gastroesophageal reflux disease, scleroderma, and SS. Her systemic medications included esomeprazole 22.3mg, fish oil, and folic acid, as well as the combination of amlodipine 2.5mg and pilocarpine hydrochloride 5mg for management of her scleroderma and SS.

The patient was oriented to person, place, and time and was of normal affect. Uncorrected distance visual acuity was 20/70-1 OD and 20/40-2 OS. Distance pinhole visual acuity was 20/40-1 OD and 20/25-1 OS, with an uncorrected near vision of 20/20-2 OD. Pupils were equal, round, and reactive to light and there was no relative afferent pupillary defect (RAPD) noted. Slit lamp biomicroscopy revealed moderate meibomian gland dysfunction (MGD), telangiectasia, and trace scurf OU. The tear film showed debris and an instantaneous tear break up time (TBUT) OU. The conjunctiva revealed 2+ superior and temporal injection OU. The right cornea showed 2+ inferior punctate epithelial erosions (PEE) with positive sodium fluorescein staining. The left cornea showed diffuse coalesced PEE central and inferior with positive sodium fluorescein staining, diffuse endothelial pigment, and mucus debris. Anterior segment examination was otherwise unremarkable and no lagophthalmos was noted with the Korb-Bkackie lid light test OU.

Due to the cornea and eyelid appearance along with the current multiple-therapy treatment regimen, the patient was diagnosed with punctate keratitis OU (OS worse than OD), MGD OU, and KCS due to secondary SS OU. The patient was directed to continue current medications: cyclosporine 0.05% ophthalmic solution BID OU, preservative-free artificial tears eight times per day OU, and 0.02% hypochlorous acid lid spray QD OU. She was additionally started on autologous serum (AS) tears 50% every two hours OU. InSight (Metro Optics; Austin, Texas) scleral contact lenses were ordered empirically for a future fitting with the goal of improving the ocular surface appearance.

#### FOLLOW UP #1

The patient returned one month later for a dry eye evaluation. She reported good compliance with the recommended treatment stating a subjective improvement in ocular comfort with mild to moderate fluctuations in vision, OS worse than OD. Uncorrected distance visual acuity was 20/60+1 OD and 20/40+1 OS with distance pinhole visual acuity of 20/30-2 OD and 20/30-2 OS. Pupils were equal, round, and

reactive to light, with no RAPD noted. Slit lamp biomicroscopy revealed similar findings to the previous exam: moderate MGD, telangiectasia, and trace scurf OU with slightly improved hyperemia along the eyelid margin OS. The tear film, conjunctiva, and cornea showed no improvement OU.

Given the stable eyelid appearance and persistent central PEE OS causing reduced vision in her distance monovision eye, treatment with an amniotic membrane OS was recommended. An amniotic membrane was applied OS without complications and a -2.50 D sphere Biofinity® (CooperVision; Lake Forest, California) soft contact lens was inserted in the right eye to correct for distance. The patient was directed to discontinue all topical medications OS and continue cyclosporine 0.05% ophthalmic solution BID OD and preservative-free artificial tears as needed OD.

#### FOLLOW UP # 2

The patient returned three days later for evaluation post amniotic membrane application OS. She noted significant improvement in both comfort and vision OS and was satisfied with the distance vision OD provided by the soft contact lens. Corrected distance visual acuity OD was 20/20 and uncorrected distance visual acuity OS was 20/40+2, with distance pinhole acuity OS of 20/30-2. Slit lamp examination showed improved eyelid hyperemia and PEE OS with the amniotic membrane ring in place. Successful removal of the ring OS and contact lens OD was completed in office. The possible need for the use of a second amniotic membrane OS if central PEE persisted was discussed with the patient. She was advised to re-initiate all medical therapies: cyclosporine 0.05% ophthalmic solution BID OU, AS tears 50% every two hours OU, preservative-free artificial tears as needed OU, and 0.02% hypochlorous acid lid spray QD OU.

#### FOLLOW UP #3

The patient returned two weeks after removal of the amniotic membrane OS reporting good compliance with the recommended treatment and continued to demonstrate overall improvement in comfort and vision OS.

Uncorrected visual acuity remained stable OU. Slit lamp biomicroscopy revealed stable central PEE OS with trace diffuse injection OU. Due to improvement in symptoms and decreased inflammation of the ocular surface, the previously ordered InSight scleral contact lens was applied in office on the left eye. Vision OD was found to be 20/100 uncorrected with distance pinhole acuity of 20/40+2 and near acuity of 20/20. The visual acuity OS was 20/30+2 with the scleral lens and a pinhole acuity OS of 20/25+1 (corrected for monovision with OD for near, OS for

distance). The lens parameters were 7.0 mm base curve, 15.2 mm diameter, -11.37 D sphere power, and standard peripheral curves. It was ordered with Hydra-PEG® (Tangible Science; Redwood City, California), a polymer coating that improves lens surface wettability.<sup>8</sup> The lens was determined to be an adequate initial fit with 499 um central fluid reservoir, measured by anterior segment optical coherence tomography (AS-OCT), adequate limbal clearance and good edge alignment OS. Application and removal training was successfully completed in office.

The patient was directed to begin daily scleral contact lens wear OS, filling the contact lens bowl with sodium chloride inhalation solution 0.9% along with carboxymethylcellulose sodium 1% ophthalmic solution to prevent insertion bubbles. She was advised to continue using cyclosporine 0.05% ophthalmic solution BID OU (pre/post scleral lens wear OS), 0.02% hypochlorous acid lid spray QD OU, and AS tears 50% every two hours OD. She was advised to decrease AS tears 50% to BID pre/post scleral lens wear OS. Additionally, the use of preservative-free artificial tears at least QID OS while wearing the scleral contact lens was recommended.

#### FOLLOW UP # 4

The patient returned three weeks later for follow-up and reported satisfactory comfort and vision with scleral lens wear for 10 hours per day OS. She stated good compliance with proper lens care and medical treatments as directed.

On examination, the uncorrected vision OS was 20/100 with a pinhole acuity of 20/40 and near acuity of 20/20. Corrected vision OS with the scleral lens was 20/40+ and improved to 20/20 with a -1.00 DS over refraction. AS-OCT showed 399 um of central fluid reservoir, adequate limbal clearance, and a well-aligned edge without impingement after wearing the lens for 6 hours (see Figure 1). Slit lamp biomicroscopy showed only mild debris in the fluid reservoir. After removal of the lens, the cornea was assessed OS showing improved trace PEE, greatest in the interpalpebral zone.

Due to the significant improvement in corneal appearance following scleral lens wear OS, the patient was advised to continue the current treatment plan. The scleral lens was re-ordered OS to account for the over refraction (7.0mm base curve, 15.2 diameter, -12.37D power, and Hydra-PEG® coating). The lens was shipped directly to the patient's home address.

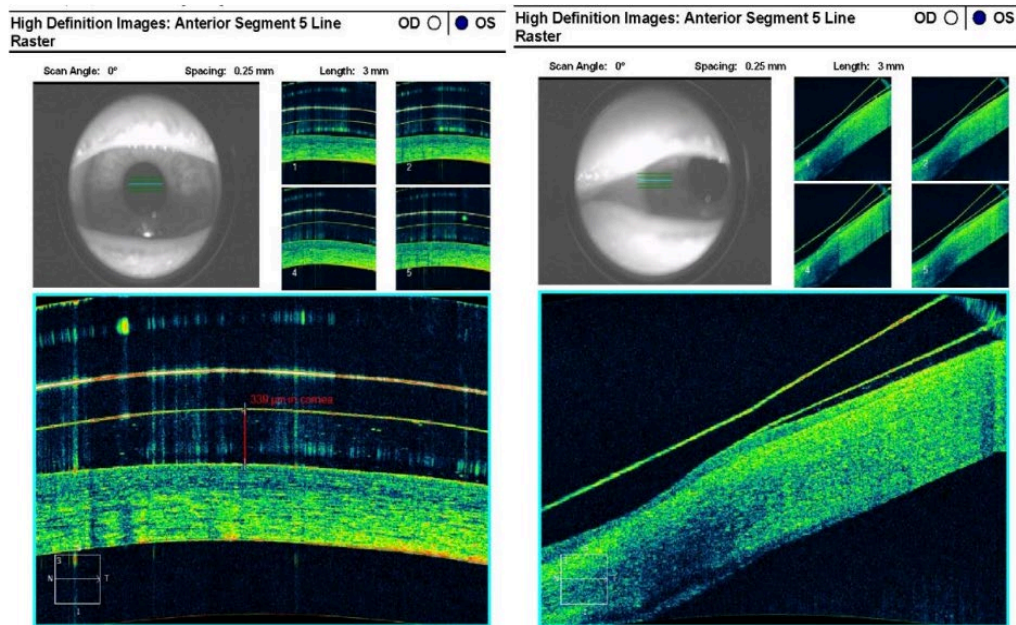


Figure 1: AS-OCT of the scleral contact lens OS showing 399 um of apical clearance and adequate limbal clearance after 6 hours of lens wear.

#### FOLLOW UP # 5

The patient returned one month after receiving the modified scleral lens with reports of great vision and comfort with the new scleral contact lens OS. Uncorrected vision remained stable OD. Corrected distance visual acuity with the scleral lens OS was 20/20 with a plano sphere over-refraction. After removal of the lens OS, the cornea was evaluated, and no signs of corneal staining were noted. This lens was determined to have an ideal fit providing excellent vision and corneal clarity.

#### DISCUSSION

KCS, or DES, is a multifactorial disorder, which often presents with irritation, fluctuation in vision, or irregularities in ocular surface epithelial appearance.<sup>9,10</sup> Such changes can significantly impact the ability to perform daily tasks and can be aggravated by environmental conditions.<sup>6</sup> Dry eye syndrome can be categorized into aqueous deficient dry eye or evaporative dry eye (Sjogren's vs. non-Sjogren's). Evaporative DES occurs due to lipid deficiency within the tear film as a result of MGD. Aqueous deficient DES, on the other hand, represents a reduced tear volume in the presence of normal lipid content and evaporation rate.<sup>3,10</sup> The most recent

classification by The Tear Film and Ocular Surface Society's Dry Eye Workshop II (TFOS DEWS II) considers KCS a continuum of both categories.<sup>3</sup>

SS is a chronic, inflammatory autoimmune disease that affects numerous exocrine glands, in particular the lacrimal gland, and is classified as primary or secondary.<sup>5,6,9,10</sup> Primary SS occurs as an independent disease without concurrent autoimmune rheumatic disease while secondary SS is associated with another rheumatic disease such as rheumatoid arthritis or scleroderma.<sup>6</sup> This case study focused on aqueous deficient dry eye, specifically related to secondary Sjogren's syndrome as the patient concurrently had a diagnosis of scleroderma. While systemic scleroderma can cause ocular manifestations including KCS, it is more likely that this condition caused exacerbation of the patient's SS leading to the observed corneal findings and patient symptoms. Scleroderma may cause eyelid changes such as lagophthalmos and telangiectasia as well as KCS.<sup>11</sup> The patient did not exhibit signs of lagophthalmos, and her telangiectasia was managed concurrently with her MGD using thermal pulsation treatment and maintenance hypochlorous acid lid spray. (The authors of this report acknowledge that other autoimmune conditions can play a role, but chose to focus the discussion on treating the patient's ocular manifestations of secondary SS.)

The main lacrimal gland is destroyed in SS via lymphocyte infiltration.<sup>6,9</sup> As a result of this process, the lacrimal gland is unable to produce adequate basal or reflex tears.<sup>12</sup> The aqueous portion of the tears is made up of secretions from the lacrimal gland primarily, as well as from several accessory glands located within the conjunctival fornix and tarsal plates (glands of Krause and glands of Wolfring, respectively).<sup>7,10</sup> The accessory lacrimal glands account for roughly 10% of the total aqueous secretion; however, it remains unclear whether or not these accessory glands can provide adequate tear volume to prevent KCS.<sup>7,13</sup> The importance of tear components, including epithelial growth factor (EGF) and vitamin A, have been found to play a vital role in the proliferation, differentiation, and maturation of epithelial cells across the ocular surface.<sup>10</sup> The lack of tear production from the main lacrimal gland in SS leads to a compromised ocular surface epithelium and resulting dry eye symptoms.<sup>7,9,10,13</sup> An insufficient pre-corneal tear film leads to a poor refractive surface and resultant blurred vision.<sup>10</sup> As demonstrated by this case, signs and symptoms of dry eye due to SS can be persistent regardless of many treatment approaches, making management extremely challenging.

## DIAGNOSIS

Clinical diagnosis of KCS is often based on a combination of patient symptoms, ocular signs, and in-office testing. As patient symptoms can be variable, especially



in the course of SS, clinicians often rely on simple, in-office tests. Such testing can include Schirmer I/II testing, TBUT, sodium fluorescein staining, and tear osmolarity.<sup>14,15</sup> Schirmer testing is used to quantify tear total secretion and is most commonly performed without anesthesia providing a measurement of reflex tearing (Schirmer I). Less frequently, the inclusion of anesthetic can be used to test basal secretion (Schirmer II).<sup>15</sup> As the patient in this case presented with a known diagnosis of KCS due to secondary SS, repeat Schirmer testing was not considered essential in the management course by the authors of this report. The TBUT helps to identify any instability of the tear film and leads to a diagnosis of evaporative DES.<sup>15</sup> However, research has demonstrated no clear difference in TBUT values between aqueous deficient DES and evaporative DES further solidifying the more recent continuum of KCS put forth by TFOS DEWS II.<sup>3,15,16</sup> The presence or absence of ocular surface staining can help to gauge the severity of KCS.<sup>15</sup> In addition, it has been shown that patients with SS often have more severe ocular surface staining as compared to patients without SS.<sup>15</sup> For the patient in this case, corneal staining was utilized as one of the main measures of monitoring for improvement with introduction of each new treatment. Tear film osmolarity has been recognized as one of the most reliable indicators of KCS. Osmolarity is measured with the use of devices such as TearLab (TearLab Corporation; San Diego, CA), which provides quantifiable data to monitor osmolarity from visit to visit.<sup>1,13,15</sup> The biggest limitation in measuring osmolarity in this patient was the lack of instrumentation. Finally, post-LASIK dry eye is a well-known condition which can complicate management of KCS. While not considered essential by the authors of this report, corneal sensitivity testing may be done for patients with a history of LASIK.

#### TREATMENT AND MANAGEMENT

Although the patient had a concurrent diagnosis of MGD, her persistent corneal findings were more related to aqueous deficient dry eye due to secondary SS and will be the focus of this discussion. Briefly, her MGD treatments included 0.02% hypochlorous acid lid spray and Lipiflow® thermal pulsation treatment. For this patient, many treatments for KCS were found to be unsuccessful long-term. While initial treatments of cyclosporine 0.05% ophthalmic solution, preservative-free artificial tears, and 0.02% hypochlorous acid lid spray were found to be somewhat adequate maintenance therapy, they did not allow for tolerable comfort or lasting corneal clarity. The patient continued to return with complaints of minimal improvement in comfort and showed unwavering reduced visual acuity. The initiation of AS tears 50% allowed the first subjective report of improved comfort. Drastic improvement in visual acuity was not observed until the placement of an amniotic membrane rehabilitated the cornea. To maintain the improved ocular

surface, a scleral lens was introduced. Once a satisfactory lens fit was obtained, the corneal appearance, as well as visual acuity, was found to remain stable at a satisfactory level.

TFOS DEWS II proposed a stepwise management plan for treating dry eye disease.<sup>17</sup> This list included all the treatments for our patient. However, it was acknowledged that the proposed management algorithm does not need to be followed linearly, due to the varying severity and signs from patient to patient.<sup>18</sup> This may make it difficult to determine when to implement each management option. In the case of this patient, the authors believed that addressing the ocular inflammation first – with existing prescription topical therapy, and introduction of AS tears and amniotic membrane placement – helped to facilitate a successful therapeutic scleral lens fitting necessary to sustain the improved signs and symptoms.

For the treatment of KCS in patients with SS, AS tears have been found to be beneficial over the use of artificial tears alone.<sup>9</sup> AS tears are made using a variable combination of the patient's whole blood diluted in either hyaluronic acid or sterile saline, and contain nutrients such as Vitamin A and epithelial growth factors, which are typically found on the ocular surface.<sup>9,10</sup> With regular use, AS tears allow these vital nutrients lost in KCS to be replenished.<sup>14</sup> The tear-like biochemical make-up of AS tears allows for improved viability, proliferation, and migration of the epithelial cells present on the ocular surface.<sup>3</sup> The most common concentration of serum in AS tears used is 20%, however higher concentrations up to 50% may be used for more severe cases.<sup>9,12</sup> As no preservatives are used in the formulation of AS tears, it is necessary to store the drops in the refrigerator between uses. Such precautions can allow for preservation of the tears for up to one month.<sup>9,12</sup>

The use of human amniotic membrane has been shown to be beneficial as an in-office treatment of many ocular surface conditions. The main beneficial properties include acting as a barrier allowing the cornea to heal, reducing friction between the eyelids and ocular surface, allowing for increased comfort, and promoting epithelial growth while inhibiting cell death.<sup>19</sup> The amniotic membrane is comprised of three distinct layers: the epithelium, stroma, and basement membrane. The hyaluronic acid present in the stroma plays an important role of reducing inflammation by decreasing cytokine expression.<sup>14,19</sup> Generally, the membrane will dissolve over the course of one week with the most common side effects being blurred vision and mild irritation due to the polycarbonate ring.<sup>19</sup> In the case of this patient, historical use of an amniotic membrane provided initial improvement in vision and comfort; however, these results were insufficient long-term. The short-

term benefits of the amniotic membrane were able to be maintained with the introduction of a scleral lens.

Research has shown the benefits of scleral lens therapy for the management of severe ocular surface disease, especially in cases when conventional dry eye treatments have failed.<sup>20-22</sup> Scleral lenses are designed to vault the cornea while maintaining a tear reservoir between the posterior lens surface and the anterior corneal surface.<sup>23,24</sup> This design allows the cornea to be continually bathed with fluid and shields it from air exposure as well as friction generated by blinking. The environment set up by the scleral lens allows the corneal epithelium to properly heal, improving comfort, vision, and symptoms.<sup>8</sup> The patient's scleral lens was ordered with Hydra-PEG® which is a polymer coating designed to improve lens wettability, TBUT, deposit resistance, and lubricity.<sup>8</sup> Scleral lenses treated with this coating have been shown to provide superior comfort and improved dry eye symptoms compared to untreated lenses.<sup>8</sup> As seen in this case, it is often beneficial to combine the use of scleral lenses with other modalities of treatment such as topical lubricants, AS tears, or cyclosporine. Tear osmolarity is widely accepted as one of the best markers for KCS.<sup>2,3,10,13,24</sup> There has been a strong correlation documented between tear osmolarity and the severity of KCS.<sup>25</sup> One study showed a statistically significant reduction and maintenance of the tear film osmolarity after 12 months of scleral contact lens wear.<sup>24</sup> Although tear osmolarity was not measured in this case due to unavailable resources, it likely that a reduced osmolarity would have been observed after 12 months of scleral lens wear.

## CONCLUSION

This case illustrates the challenges in the treatment of persistent dry eye disease due to secondary SS. The lack of basal and reflex tears, due to infiltrative damage to the lacrimal gland, leads to a damaged ocular surface epithelium and resultant reduced vision.<sup>6,10</sup> The use of AS tears was found to be beneficial in replenishing the vital growth factors and vitamins normally present in healthy tears allowing for proper epithelial growth and proliferation.<sup>2</sup> Frequent use of AS tears by this patient provided rapid subjective improvement in ocular comfort and vision. In-office amniotic membranes have been successfully used in the management of ocular surface disease. The membrane acts as a platform to allow epithelial regrowth while halting inflammation.<sup>4</sup> The use of an amniotic membrane for this patient allowed for rapid improvement in the corneal clarity and visual acuity.

While the use of AS tears and amniotic membranes allowed for subjective and clinical improvement, maintenance of corneal integrity was not successfully obtained until the introduction of a scleral lens. This patient benefited from the

unique design of this scleral lens which allowed the corneal surface to be immersed in an oxygenated solution while being protected from environmental threats. This environment allowed the corneal epithelium to heal without hindrance from external forces.<sup>7</sup> The combination of AS tears and the use of an amniotic membrane developed a stable ocular surface, setting the stage for a more ideal scleral contact lens fit. Regular wear of a scleral lens by this patient resulted in long-term improvement in clinical appearance of the corneal epithelium as well as stable visual acuity. This combination treatment modality allowed for the most consistent visual and physical comfort compared to all other treatments attempted.

#### REFERENCES

1. Gonzales JA, Shiboski SC, Bunya VY, et al. Ocular clinical signs and diagnostic tests most compatible with keratoconjunctivitis sicca: A latent class approach. *Cornea*. 2020;39(8):1013-1016. doi: [10.1097/ICO.0000000000002311](https://doi.org/10.1097/ICO.0000000000002311)
2. 2007 Report of the International Dry Eye Workshop (DEWS). *Ocul Surf*. 2007;5(2 special issue):1-142. <https://www.tearfilm.org/dewsreport/pdfs/TOS-0502-DEWS-noAds.pdf>
3. Craig JP, Nichols KK, Akpek EK, et al. TFOS DEWS II Definition and Classification Report. *Ocul Surf*. 2017;15(3):276-283. doi: [10.1016/j.jtos.2017.05.008](https://doi.org/10.1016/j.jtos.2017.05.008)
4. Shimazaki J, Goto E, Ono M, Shimmura S, Tsubota K. Meibomian gland dysfunction in patients with Sjogren syndrome. *Ophthalmology*. 1998;105(8):1485-1488. doi: [10.1016/S0161-6420\(98\)98033-2](https://doi.org/10.1016/S0161-6420(98)98033-2)
5. Sullivan DA, Dana R, Sullivan RM, et al. Meibomian gland dysfunction in primary and secondary sjögren syndrome. *Ophthalmic Res*. 2018;59(4):193-205. doi: [10.1159/000487487](https://doi.org/10.1159/000487487)
6. Kassan SS, Moutsopoulos HM. Clinical manifestations and early diagnosis of Sjögren syndrome. *Arch Intern Med*. 2004;164(12):1275-1284. doi: [10.1001/archinte.164.12.1275](https://doi.org/10.1001/archinte.164.12.1275)
7. Conrady CD, Joos ZP, Patel BCK. Review: The lacrimal gland and its role in dry eye. *J Ophthalmol*. 2016. doi: [10.1155/2016/7542929](https://doi.org/10.1155/2016/7542929)
8. Mickles C, Harthan J, Barnett M. A surface treatment solution for scleral lens wearers with dry eye. Presented at: Global Specialty Lens Symposium. ;January 26, 2019. <https://tangiblescience.com/wp-content/uploads/2019/01/Final-GSLS-2019-Mickles-Tangible-Paper-Presentation.pdf>
9. Tsubota K, Goto E, Fujita H, et al. Treatment of dry eye by autologous serum application in Sjogren's syndrome. *Br J Ophthalmol*. 1999;83(4):390-395. doi: [10.1136/bjo.83.4.390](https://doi.org/10.1136/bjo.83.4.390)

10. Bron AJ, de Paiva CS, Chauhan SK, et al. TFOS DEWS II pathophysiology report. *Ocul Surf*. 2017;15(3):438-510. doi: [10.1016/j.jtos.2017.05.011](https://doi.org/10.1016/j.jtos.2017.05.011)
11. Tailor R, Gupta A, Herrick A, Kwartz J. Ocular manifestations of scleroderma. *Surv Ophthalmol*. 2009;54(2):292-304. doi: [10.1016/j.survophthal.2008.12.007](https://doi.org/10.1016/j.survophthal.2008.12.007)
12. Geerling G, MacLennan S, Hartwig D. Autologous serum eye drops for ocular surface disorders. *Br J Ophthalmol*. 2004;88(11):1467-1474. doi: [10.1136/bjo.2004.044347](https://doi.org/10.1136/bjo.2004.044347)
13. Willcox MDP, Argüeso P, Georgiev GA, et al. TFOS DEWS II tear film report. *Ocul Surf*. Published online 2017. doi: [10.1016/j.jtos.2017.03.006](https://doi.org/10.1016/j.jtos.2017.03.006)
14. Thulasi P, Djalilian AR. Update in current diagnostics and therapeutics of dry eye disease. *Ophthalmology*. 2017;124(11S):S27-S33. doi: [10.1016/j.ophtha.2017.07.022](https://doi.org/10.1016/j.ophtha.2017.07.022)
15. Beckman KA, Luchs J, Milner MS. Making the diagnosis of Sjögren's syndrome in patients with dry eye. *Clin Ophthalmol*. 2015;10:43-53. doi: [10.2147/OPHTH.S80043](https://doi.org/10.2147/OPHTH.S80043)
16. Lemp MA, Crews LA, Bron AJ, Foulks GN, Sullivan BD. Distribution of aqueous-deficient and evaporative dry eye in a clinic-based patient cohort: A retrospective study. *Cornea*. 2012;31(5):472-478. doi: [10.1097/ICO.0b013e318225415a](https://doi.org/10.1097/ICO.0b013e318225415a)
17. Jones L, Downie LE, Korb D, et al. TFOS DEWS II management and therapy report. *Ocul Surf*. 2017;15(3):575-628. doi: [10.1016/j.jtos.2017.05.006](https://doi.org/10.1016/j.jtos.2017.05.006)
18. Craig JP, Nelson JD, Azar DT, et al. TFOS DEWS II report executive summary. *Ocul Surf*. 2017;15(4):802-812. doi: [10.1016/j.jtos.2017.08.003](https://doi.org/10.1016/j.jtos.2017.08.003)
19. McGaughy A, Gupta P. In office use of amniotic membrane. *EyeNet*. 2015;(3):31-32. <https://www.aao.org/eyenet/article/in-office-use-of-amniotic-membrane>
20. Kok JH, Visser R. Treatment of ocular surface disorders and dry eyes with high gas-permeable scleral lenses. *Cornea*. 1992;11(6):518-522. doi: [10.1097/00003226-199211000-00006](https://doi.org/10.1097/00003226-199211000-00006)
21. Abelson M. Scleral lens effectively treats severe ocular surface disease. *Primary Care Optometry News*. 2007 Mar. <https://www.healio.com/news/optometry/20120225/scleral-lens-effectively-treats-severe-ocular-surface-disease>
22. Harthan JS, Shorter E. Therapeutic uses of scleral contact lenses for ocular surface disease: Patient selection and special considerations. *Clin Optom (Auckl)*. 2018;10:65-74. doi: [10.2147/OPTO.S144357](https://doi.org/10.2147/OPTO.S144357)

23. Rosenthal P, Croteau A. Fluid-ventilated, gas-permeable scleral contact lens is an effective option for managing severe ocular surface disease and many corneal disorders that would otherwise require penetrating keratoplasty. *Eye Contact Lens*. 2005;31(3):130-134. doi: [10.1097/01.icl.0000152492.98553.8d](https://doi.org/10.1097/01.icl.0000152492.98553.8d)
24. La Porta Weber S, Becco De Souza R, Gomes JÁP, Hofling-Lima AL. The use of the esclera scleral contact lens in the treatment of moderate to severe dry eye disease. *Am J Ophthalmol*. 2016;163:167-173. doi: [10.1016/j.ajo.2015.11.034](https://doi.org/10.1016/j.ajo.2015.11.034)
25. Suzuki M, Massingale ML, Ye F, et al. Tear osmolarity as a biomarker for dry eye disease severity. *Investig Ophthalmol Vis Sci*. 2010;51(9):4557-4561. doi: [10.1167/iovs.09-4596](https://doi.org/10.1167/iovs.09-4596)